

# Two-part fractures of the proximal humerus

Jae-Myeung Chun, MD, Gordon I. Groh, MD, and Charles A. Rockwood, Jr., MD, San Antonio, Texas

*Between 1981 and 1991, 137 patients had 141 two-part proximal humerus fractures. One hundred thirteen surgical neck, 24 greater tuberosity, 2 anatomic neck, and 2 lesser tuberosity fractures were studied. Eleven patients had died in the interim; the remaining cases were reviewed. The mean age of patients with surgical neck fractures was 57 years (range 20 to 91 years), and 62.8% (71 cases) were women. In 38% of cases there was another significant medical problem. Eighty (70.8%) cases were treated with a sling and early isometric and pendulum exercises. Bony union was obtained in an average of 3.2 months (range 2 to 8 months), and 87.5% achieved satisfactory function. The mean age of patients with greater tuberosity fractures was 37 years (range 20 to 59 years), and 79.2% (19 cases) were men. Ten (41.7%) cases were treated with open reduction and internal fixation, and the remainder were treated without surgery. All patients improved to a satisfactory level of function. Anatomic neck fractures (two) were treated with surgery. Lesser tuberosity fractures (two) were treated conservatively and had good functional results. It appears that conservative measures when coupled with early isometric and pendulum exercises produce a satisfactory result in surgical neck fractures. Similarly, conservative treatment for nondisplaced greater tuberosity fractures and operative intervention for displaced fractures resulted in satisfactory function. Lesser tuberosity fractures without limitation of motion appear to do well with a sling and early motion. (J SHOULDER ELBOW SURG 1994;3:273-87.)*

**A** proximal humerus fracture is a fracture at or proximal to the surgical neck of humerus.<sup>13, 23, 45, 55</sup> Proximal humerus fractures make up approximately 5% of all bony injuries and about 45% of all humerus fractures. In patients older than 40 years of age, about 75% of humerus fractures occur in this proximal area.<sup>23, 40, 55</sup> Mills and Horne have characterized the proximal humerus fracture as "the unsolved fracture."<sup>45</sup> In 1934 Codman<sup>9</sup> described proxi-

mal humerus fractures as usually occurring along the epiphyseal scar, leading to a concept of proximal fractures composed of four segments. In 1970, using a series of 300 displaced proximal humerus fractures, Neer<sup>48</sup> described a four-segment classification system consisting of the articular segment, shaft, greater tuberosity, and lesser tuberosity. In this classification when any of the four major segments is displaced more than 1 cm or is angulated more than 45°, the fracture is considered displaced. Many classification systems have been proposed,\* and debate has occurred about the difficulty and reproducibility of Neer's classification,<sup>26, 33</sup> but Neer's classification is the most widely used system.<sup>3, 4</sup>

From the Shoulder Service, Department of Orthopaedic Surgery, University of Texas Health Science Center, San Antonio.

Reprint requests: Charles A. Rockwood, Jr., MD, Professor and Chairman Emeritus, University of Texas Health Science Center at San Antonio, 7703 Floyd Curl Dr., San Antonio, TX 78284.

Copyright © 1994 by Journal of Shoulder and Elbow Surgery Board of Trustees.

1058-2746/94/\$3.00 + 0 **32/1/58929**

\*References 11, 14, 26, 29, 30, 33, 58.

**Table I** Questionnaire form

<b>Pain</b>		
Is your injured shoulder still painful?	( ) Yes	( ) No
If yes,		
Severe (complete disabled)		
Marked (serious limitation)		
Moderate (interferes with some activities)		
Mild (only after unusual activity)		
<b>Function</b>		
Are you able to do all the things you could do before injury?	( ) Yes	( ) No
If no, please grade your ability to perform these activities according to this system.		
1. Normal		
2. Difficult		
3. Unable to do without aid		
4. Unable to do even with aid		
All responses are regarding your injured shoulder.		
1. Use back pocket	( )	
2. Perineal/toilet care	( )	
3. Wash opposite armpit	( )	
4. Eat with utensil	( )	
5. Comb hair	( )	
6. Use hand with arm at shoulder level	( )	
7. Carry 10 lb with arm at side	( )	
8. Dress yourself	( )	
9. Sleep on injured side	( )	
10. Pull an object toward yourself	( )	
11. Use hand overhead	( )	
12. Throw	( )	
13. Lift	( )	
14. Do usual work	( )	
15. Do usual sport	( )	
<b>Other subjective evaluation</b>		
How would you describe the strength of your injured shoulder?		
( ) Normal ( ) Good ( ) Fair ( ) Poor ( ) Terrible		
How would you describe the stability of your injured shoulder?		
( ) Normal ( ) Good ( ) Fair ( ) Poor ( ) Terrible		
How would you describe the range of motion of your injured shoulder?		
( ) Normal ( ) Good ( ) Fair ( ) Poor ( ) Terrible		

For pain 0 points for severe, 10 points for marked, 20 points for moderate, 30 points for mild, and 40 points for no pain were given. For function 2 points for normal, 1 point for difficult, 0.5 points for unable to do without aid, and 0 points for unable to do even with aid were given. For other subjective evaluation 10 points for normal, 7.5 points for good, 5 points for fair, 2.5 points for poor, and 0 points for terrible were given. A total score greater than 90 points was considered excellent, scores between 76 and 90 good, 60 to 75 points fair, and less than 60 points poor. We concluded that scores greater than 60 points were acceptable for usual daily function in elderly individuals.

The most common type of the displaced proximal humerus fracture is the two-part fracture of Neer's classification.<sup>23, 45</sup> Two-part fractures include surgical neck fractures, anatomic neck fractures, greater tuberosity fractures, lesser tuberosity fractures, and fracture dislocations.<sup>48</sup> Fortunately most fractures are minimally displaced and are easily treated by immobilization and early motion.<sup>10, 48</sup> But a therapeutic dilemma has been posed in treating displaced frac-

tures.<sup>3, 4, 36, 63</sup> Previous studies have included all or several types of fractures or three- and four-part fractures only.\* Some included all age groups.<sup>14, 51, 67</sup> It has been difficult to assess the outcome of the two-part fracture in adults from the heterogeneity of these series. The purpose of this study is to review our experience in treat-

\*References 8, 13, 22, 27, 38, 39, 45, 47, 49, 56, 62-65.

ing two-part fractures in adults, to discuss the rationale of treatment methods, and to provide guidelines for the management of these fractures.

### MATERIAL AND METHODS

From 1981 to 1991, 870 patients with proximal humerus fractures were treated in the Department of Orthopaedics at the University of Texas Health Science Center at San Antonio. We excluded patients younger than 20 years of age, patients with pathologic fractures, patients with injuries more than 2 weeks old, and referred patients with complications. One hundred thirty-seven patients had 141 two-part proximal humerus fractures according to Neer's criteria for classification. Age, sex, mechanism of injury, radiographic findings, hand dominance, neurovascular injury, associated injuries, associated medical problems, method of treatment, duration for appearance of callus and union, and complications were analyzed. A final assessment was determined with a combination of chart review, examinations, and questionnaires according to a modified Neer's method (Table I).<sup>48</sup> A score greater than 90 points was considered excellent, scores between 76 and 90 good, 60 to 75 points fair, and less than 60 poor. A score greater than 60 was considered an acceptable functional result. During the study period 11 patients died, and one patient had hemiplegia in the involved side. These 12 cases could not be assessed for final outcome. Data obtained were statistically analyzed with a two-way analysis of variance, and an unpaired *t* test was used to further evaluate the data.

**Surgical neck fractures.** The method of treatment for a surgical neck fracture was selected as follows: a sling and exercises for stable fractures with acceptable position, manipulation for fractures with unacceptable position, and skeletal traction for unstable fractures. For 104 cases a conservative treatment method was used. In 80 of these cases a sling and exercises were used. The remaining cases were treated as follows: in 13 cases skeletal traction was used. In seven cases coaptation splints were used, and in four cases hanging arm casts were used (Table II).

**Sling and exercises.** With simple immobilization of a sling or sling and swathe, the surgeon personally instructed the patient about exercises. The sling should permit the arm to

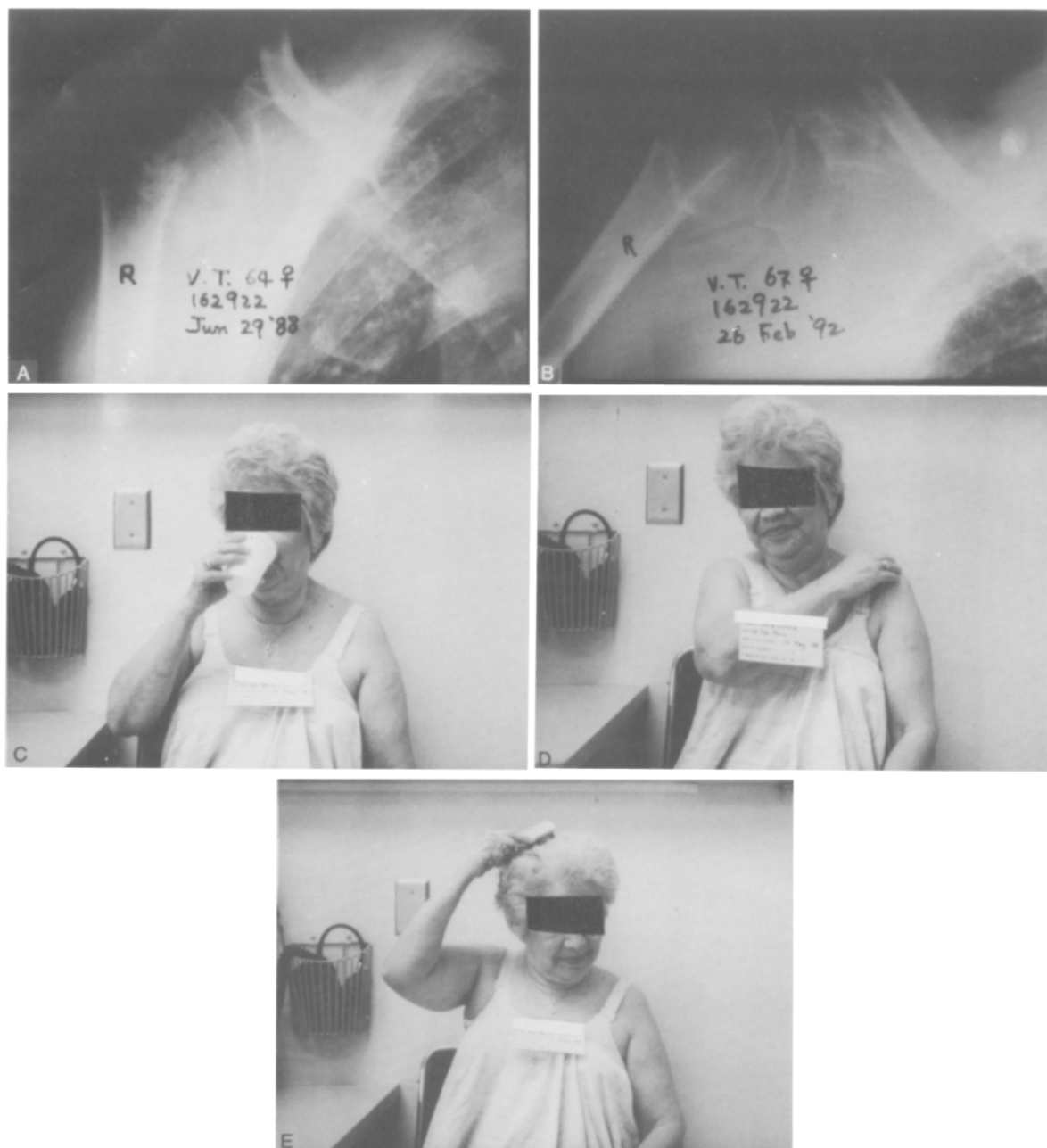**Table II** Treatment of surgical neck fractures

Type of treatment	No. of cases (%)
Conservative	
Sling and exercises	80
Skeletal traction	13
Coaptation splint	7
Hanging arm cast	4
TOTAL	104 (92)
Operative	
ORIF	4
CR & Perc pinning	2
Hemiarthroplasty	2
Debridement	1
TOTAL	9 (8)

ORIF, Open reduction and internal fixation; CR & Perc pinning, closed reduction and percutaneous pinning.

hand loosely at the side of body. Finger and wrist exercises were encouraged immediately. Gentle pendulum exercises performed six times a day without the sling were usually begun a few days after fracture. Isometric exercises were begun immediately or within 1 week of fracture. They consisted of 200 to 300 repetitions in the morning and afternoon for deltoid, biceps, and triceps muscles. In cases with significant angulation of the fracture, the isometric exercises were delayed for approximately 1 week. Increasing activities were permitted within the limit of pain for each patient. All patients had activity and exercise instructions by the surgeon and were under the surgeon's instruction during the duration of treatment (Figures 1 and 2).

**Skeletal traction.** The indications for skeletal traction were unstable fractures after reduction, failure of closed reduction, and open fractures. Skeletal traction was used in 13 cases. Overhead traction was applied through the olecranon process. When the patient complained of less pain, and early callus was apparent on radiographs, which usually occurred 3 to 4 weeks after the injury, the arm was gradually moved to the side of the patient over the course of several days. When no motion was detected at the fracture site, and good callus formation was apparent on radiographs, the traction was discontinued and a sling applied. Skeletal traction was used in nine cases of unstable reduction, three cases of failure of closed

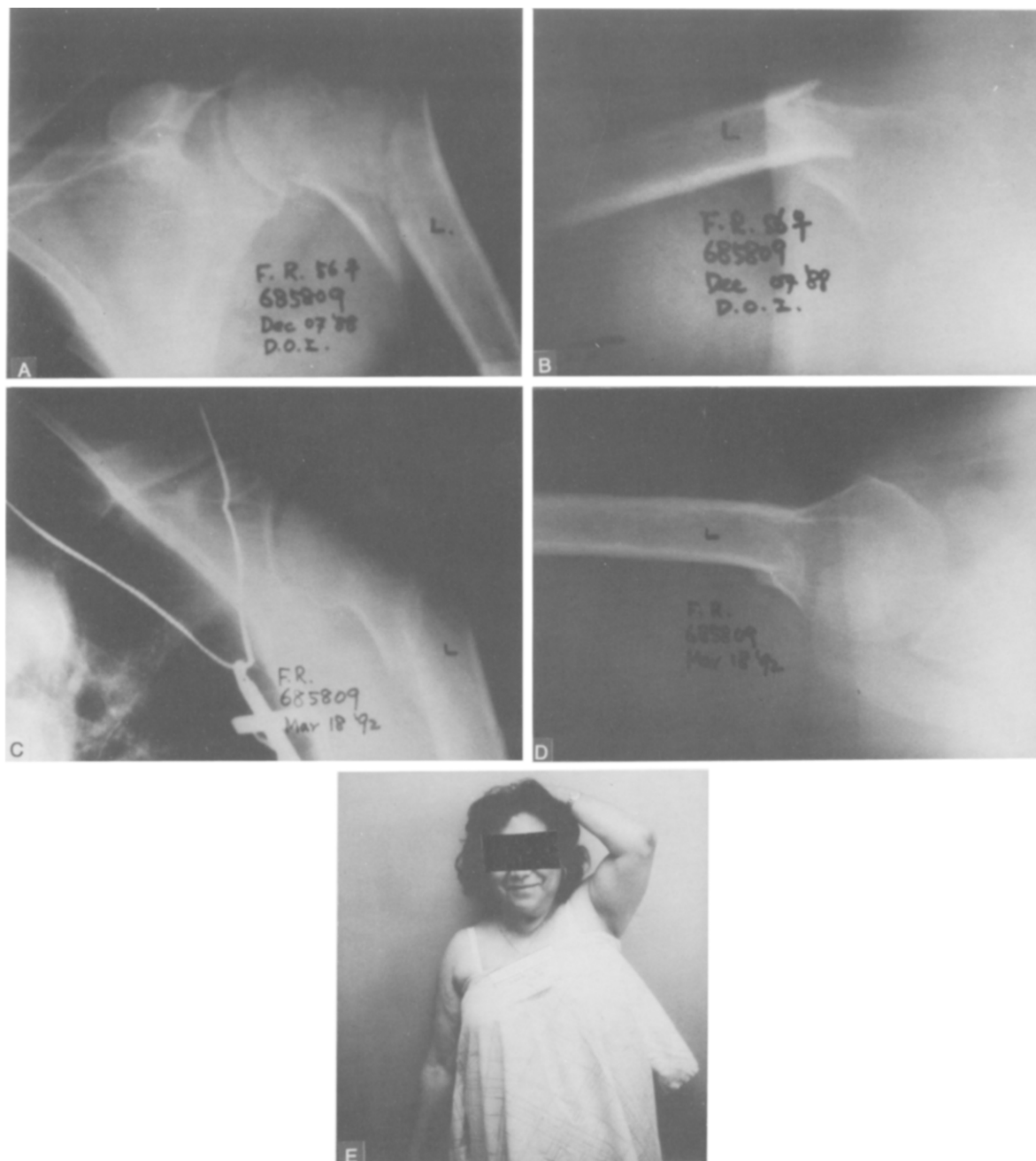


**Figure 1** Sixty-four-year-old woman who was injured by fall. Shoulder immobilizer was applied for 6 days, then changed to sling. Isometric and pendulum exercises were initiated 6 days after injury. **A**, Initial anteroposterior radiograph reveals surgical neck fracture with severe varus deformity. **B**, Four years later anteroposterior radiograph shows good bony healing with mild varus deformity. **C, D, E**, Photographs demonstrate good functional range of motion 4 years after initial injury, with score of 64 points.

reduction, and one case of open fracture resulting from gunshot injury (Figure 3).

**Hanging arm cast.** A hanging arm cast was used in four cases. In two cases it was used

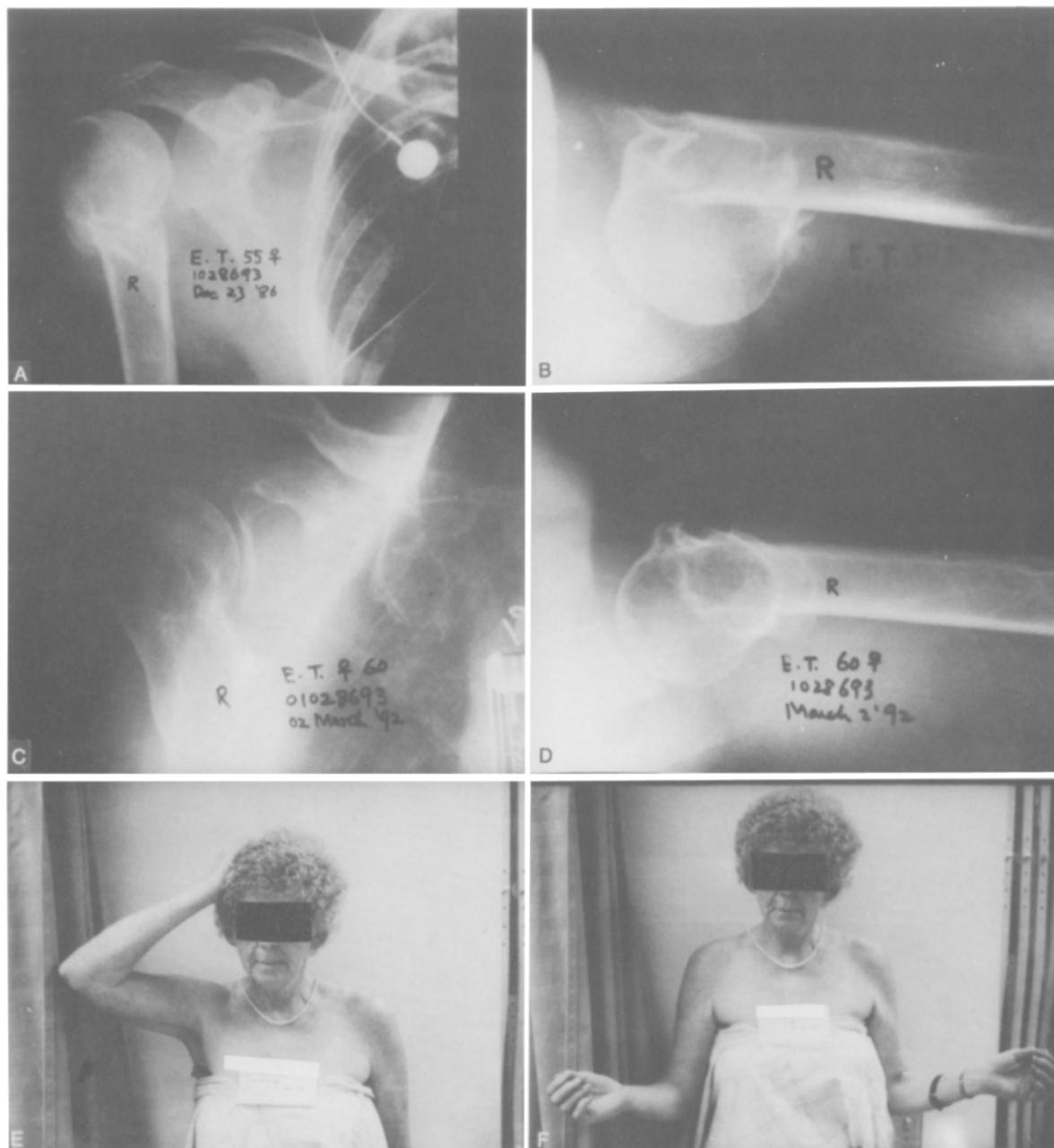after closed reductions and in two cases as the initial treatment. In one of these cases the functional result was poor. In the other case a non-union developed.



**Figure 2** Fifty-six-year-old woman who was injured by motor vehicle accident. Sling was applied, and isometric and pendulum exercises were begun 4 days after injury. **A** and **B**, Initial radiographs show comminuted surgical neck fracture with lateral displacement of shaft and anterior angulation. **C** and **D**, Anteroposterior and lateral radiographs made 4 years later demonstrate union with good alignment. **E**, Photograph made 4 years after injury shows useful range of motion, with score of 65 points.

**Manipulation.** Manipulation was used in 38 cases. Manipulation was performed with the patients under intravenous sedation or general anesthesia. The arm was brought to 90° forward

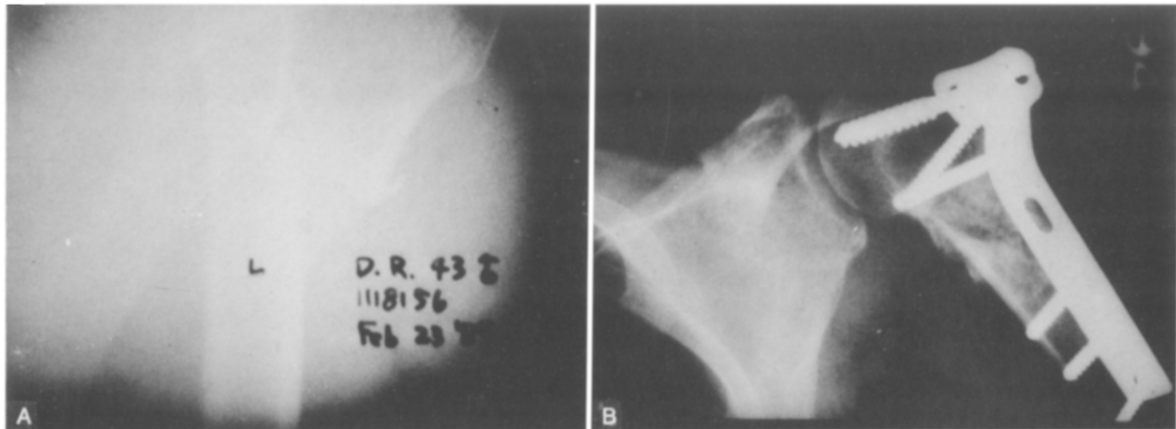
flexion and slight abduction with elbow flexion. After gentle traction closed reduction was performed according to the fracture configuration. A gentle compression force was applied over



**Figure 3** Fifty-five-year-old woman injured by motor vehicle accident. Skeletal traction was applied after failure of closed reduction. **A** and **B**, Initial anteroposterior and lateral radiographs show surgical neck fracture with medial displacement and anterior angulation. **C** and **D**, Anteroposterior and lateral radiographs made 5 years later demonstrate union with good alignment. **E** and **F**, Photographs taken 5 years after injury reveal good range of motion, with score of 73 points.

the olecranon area and along the long axis of the arm for impact of the fragments. Reduction was confirmed with anteroposterior and lateral radiographs. Criteria of reduction were less

than 45° angulation and more than 50% apposition. In elderly patients more displacement was accepted. The arm was slowly brought to the side of the body, and the stability was gently



**Figure 4** Forty-three-year-old man who was injured by motor vehicle accident. He had associated injuries including straddle fracture of pelvis, and grade II open fracture of left tibia. Operative treatment was selected to improve mobility. **A**, Initial anteroposterior radiograph shows surgical neck fracture with medical displacement of shaft. **B**, Anteroposterior radiograph, made 2 months after surgery shows good fixation with T-plate and screws and early callus formation.

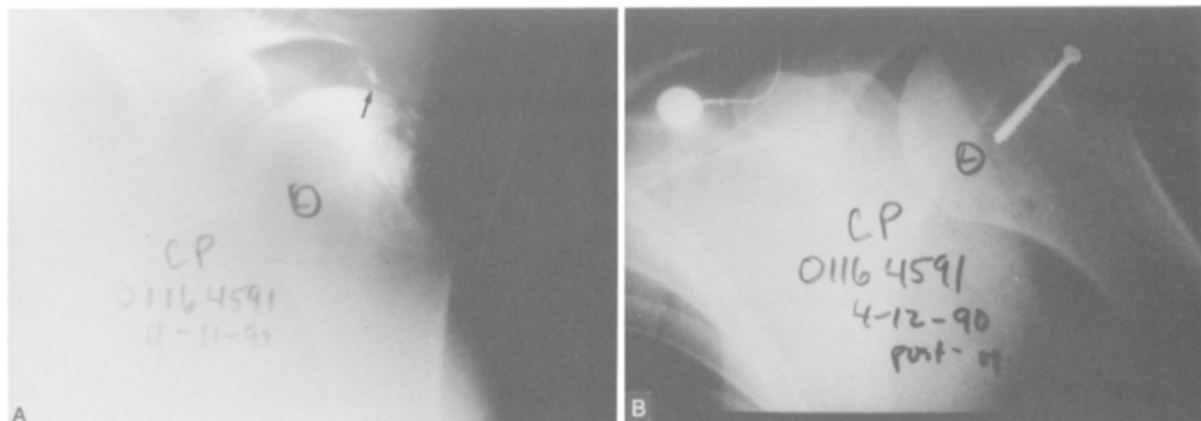
assessed. In 33 cases an acceptable reduction was obtained. For the 24 cases with a stable reduction, a sling and exercises was used in 20 cases, coaptation splints in two cases, and a hanging arm cast in two cases. In the nine cases of unstable reduction, skeletal traction was used. In five cases an acceptable reduction could not be attained. In three failed cases skeletal traction was used. In one case open reduction and internal fixation was performed. In the other failed case a patient of 84 years was treated with a sling.

**Operation.** The indications for operative treatment were failures of conservative measures, intolerance of patients to conservative treatments, selective cases of multiple trauma, and open fractures. Operative treatment was selected in nine cases: one case for open reduction and internal fixation after failure of closed reduction, two cases after failure of hanging arm casts, one case for an intolerance of a patient to skeletal traction, two cases for multiple injuries, two cases for hemiarthroplasty, and one case for wound debridement after a gunshot injury (Table II). For internal fixation a T-plate was used in three cases: percutaneous pinning for two cases and Rush rod for one case (Figure 4).

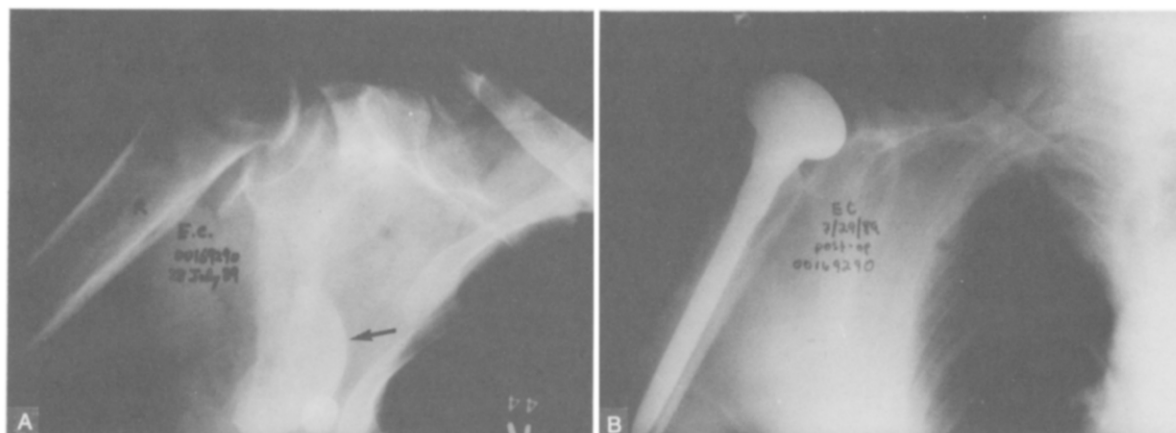
**Greater tuberosity fracture.** Greater tuberosity fractures were uncommon and were

frequently associated with anterior dislocations. In this study most of the greater tuberosity fractures occurred in young healthy men. Non-operative treatment was used in 14 cases. For 13 cases after closed reduction of dislocation, anatomic reduction of the greater tuberosity was obtained. For one case without dislocation a sling was used because of the presence of hepatic encephalopathy. Operative treatment was selected in 10 cases with more than 1 cm of displacement. Among these cases four were associated with anterior dislocations. After closed reduction of these dislocations, the greater tuberosity fragment remained displaced. Internal fixation included screws for eight cases (Figure 5) and heavy nonabsorbable cottonlike Dacron sutures (Deknatel, Fall River, Mass.) for two cases. All of the operations were performed within 2 weeks of injury.

**Anatomic neck fracture.** Anatomic neck fractures were rare in this series. Only two cases occurred, and both were associated with anterior dislocation. One case was treated by open reduction after failure of closed reduction. The procedure was completed without any internal fixation after open reduction. This choice was made because of a hypoxemic episode from pulmonary contusion, which rendered further operating time unacceptable. Bony union was obtained at 4 months; however, no further



**Figure 5** Fifty-year-old man was injured skiing. After closed reduction of dislocation, he was transferred to us. **A**, Initial anteroposterior radiograph shows comminuted fracture of greater tuberosity with severe superior displacement (*arrow*). **B**, Anteroposterior radiograph made after surgery. Main fragment was fixed with 4.0 mm cancellous screw, and rotator cuff was repaired. End result was score of 85 points.



**Figure 6** Sixty-five-year-old man who was injured by motor vehicle accident. Axillary, radial, and ulnar nerves were also injured. **A**, Initial anteroposterior radiograph shows anatomic neck fracture-dislocation with severely displaced humeral head (*arrow*). **B**, Hemiarthroplasty was performed. Radial and ulnar nerves recovered in 3 months. Axillary nerve had not recovered at 6 months, when he died in another motor vehicle accident.

follow-up for this case was available. The other case was associated with injuries of axillary, radial, and ulnar nerves. This patient was treated with a hemiarthroplasty (Figure 6), and the radial and ulnar nerves recovered in 3 months. However the axillary nerve had not recovered 6 months after surgery, when the patient died in a motor vehicle accident.

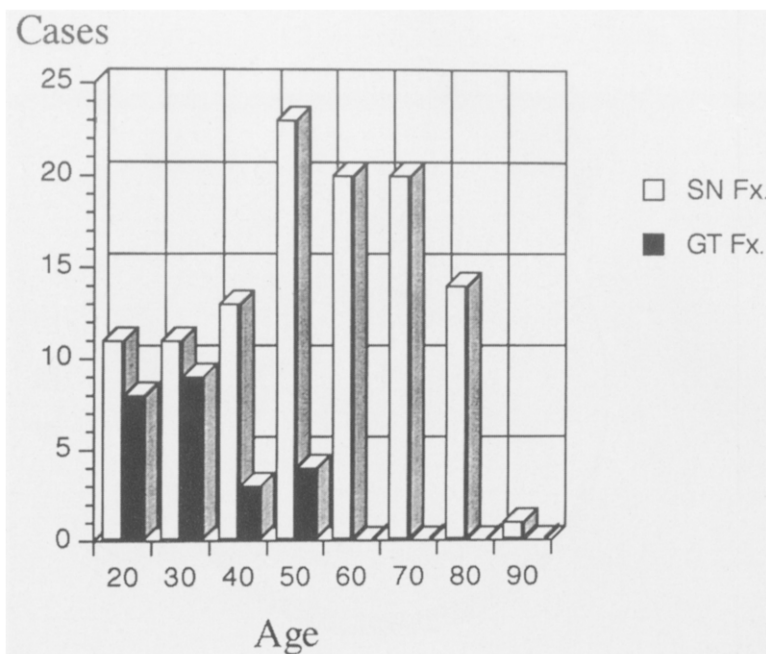
**Lesser tuberosity fracture.** Lesser tuberosity fractures were also rare with only two

cases identified. Both cases were treated without surgery with a sling and exercises. Neither case was complicated by instability, and good results were obtained in both cases.

## RESULTS

Of the 141 initial two-part proximal humerus fractures, 113 cases were surgical neck fractures, 24 cases were greater tuberosity fractures, 2 cases were anatomic neck fractures,





**Figure 7** Comparison of ages between surgical neck and greater tuberosity fractures. *SN Fx*, Surgical neck fracture; *GT Fx*, greater tuberosity fracture.

**Table III** Numbers, age, and sex of patients and cases

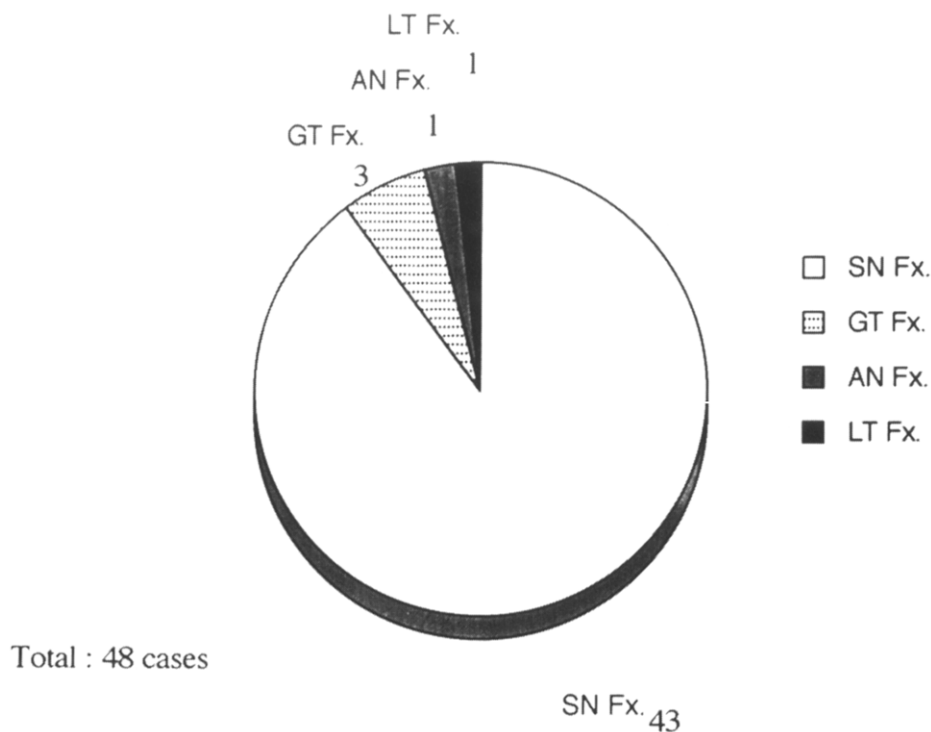
Type of fracture	Patients	Cases	F/M (cases)	Mean age (yr) (range)
SN Fx	110	113	71/42	57 (20-91)
GT Fx	23	24	5/19	37 (20-59)
AN Fx	2	2	0/2	48 (24-65)
LT Fx	2	2	0/2	37 (20-53)
All	137	141	76/65	54 (20-91)

*SN Fx*, Surgical neck fracture; *GT Fx*, greater tuberosity fracture; *AN Fx*, anatomic neck fracture; *LT Fx*, lesser tuberosity fracture.

and 2 cases were lesser tuberosity fractures. The mean age of all patients was 54 years. For surgical neck fractures the mean age was 57 years, whereas the mean age for greater tuberosity fractures was 37 years (Table III, Figure 7). Sex distribution for all cases was 76 women and 65 men (Table III). For surgical neck fractures female patients (71) were more common than male patients (42). Contrary to this finding, for greater tuberosity fractures most of the patients were men (19 men, five women, Table III). The right side was involved in 57 patients, and the left side was involved in 76 pa-

tients. Four patients had bilateral fractures. The mechanism of injury was determined to be falls in 99 cases, and 31 cases occurred by motor vehicular accidents (Table IV). Thirty-nine (27.7%) cases had some other associated injury. Most (61.5%) of the cases with associated injury were injured by motor vehicular accidents (Table V).

Eleven nerve injuries occurred in nine patients. The axillary nerve was the most commonly injured nerve, occurring in seven cases. Other nerves injured included one musculocutaneous nerve, two radial nerves, and one ulnar



**Figure 8** Significant medical problems. *SN Fx*, Surgical neck fracture; *GT Fx*, greater tuberosity fracture; *AN Fx*, anatomic neck fracture; *LT Fx*, lesser tuberosity fracture.

**Table IV** Mechanism of injury

Type of fracture	Fall	MVA	Assault	GSW	Unknown
SN Fx	81	23	5	2	2
GT Fx	18	6	2	0	0
AN Fx	1	1	0	0	0
LT Fx	1	1	0	0	0
All	99	31	7	2	2

MVA, Motor vehicular accident; GSW, gunshot wound.  
Other abbreviations as in Table III.

nerve. In nine cases the patients completely recovered clinically within 3 months from injury. One axillary nerve recovered in 5 months. One axillary nerve had not recovered at 6 months when the patient died in a motor vehicle accident. No associated vascular injuries occurred.

Significant medical problems complicated 48 cases. These medical problems included acute myocardial infarction, congestive heart failure, pulmonary disease, cirrhosis, diabetic ketoacidosis, severe alcoholism, and acquired im-

munodeficiency syndrome. The overwhelming majority of significant associated medical problems were associated with a surgical neck fracture (89.6%, Figure 8).

Fifty-six (49.6%) cases of surgical neck fractures could be assessed for a final result. Forty-nine (87.5%) cases recovered to an acceptable functional result with an average of 6.6 years (range 1 year, 6 months to 11 years, 4 months) follow-up. Six cases were rated as excellent, 25 cases as good, 18 cases as fair, and seven cases

**Table V** Cases with associated injuries

Type of fracture	Fall	MVA	Unknown	Total
SN Fx	10	18	1	29
GT Fx	3	4	0	7
AN Fx	1	1	0	2
LT Fx	0	1	0	1
All	14	24	1	39

Abbreviations as in Tables III and IV.

were rated as having a poor result. Forty-five (56.3%) of the 80 patients who were treated with a sling and exercises could be assessed. Forty-two (93.3%) cases recovered to an acceptable functional result. Seventeen (44.7%) of the 38 patients who were treated with manipulation could be assessed. Sixteen (94.1%) patients recovered to an acceptable functional result. Range of motion for the surgical neck fracture group averaged 107° (range 20° to 180°) for forward flexion and 30° (range 0° to 90°) for external rotation. The median site for internal rotation was the second lumbar spinous process (range T-6 to lateral hip). Early callus appeared at an average of 4.5 weeks (range 2 to 12 weeks), and union was obtained at an average of 3.2 months (range 2 to 8 months).

Eleven (45.8%) cases of greater tuberosity fracture could be assessed for a final result. All cases recovered to a satisfactory function with a mean follow-up of 5.1 years (range 7 months to 9 years, 4 months). One case was rated as excellent, seven cases as good, and three cases as fair. No case had a poor result. Union was obtained at an average of 2.3 months (range 2 to 4 months). Range of motion averaged 118° (range 90° to 60°) for forward flexion and 35° (range 20° to 50°) for external rotation. The median site for internal rotation was the twelfth thoracic spinous process (range T-9 to L-4). In both cases of lesser tuberosity fracture the final result was rated as good.

**Complications.** Six (4.3%) complications occurred in this series. Two nonunions occurred in this series of 113 surgical neck fractures. One fracture had been treated initially in a hanging arm cast, and the other case was initially treated with a sling; however, exercises were delayed for 4 weeks because of loss of follow-up for this patient. Other complications included one

pin migration, one pin tract infection, one Sudeck's atrophy in a surgical neck fracture, and one screw displacement in a greater tuberosity fracture. For the one nonunion osteosynthesis was done with a T-plate and bone graft, and for the other nonunion the patient's medical condition precluded operative treatment. For the case of pin migration, all pins were removed without any delay in bony healing. Infection of the pin tract resolved after removal of the pin. The case of Sudeck's atrophy also resolved after physiotherapy. The displaced screw in a greater tuberosity fracture was removed after bony union.

## DISCUSSION

Although numerous authors have reported their results in the treatment of proximal humerus fractures,\* the results are incomplete and misleading.<sup>10</sup> Most reports are extremely heterogeneous in fracture types, methods of treatment, and age of patients.† Although two-part fractures are the most common displaced proximal humerus fracture,<sup>23, 45</sup> most of these fractures are treated on an outpatient basis. This situation may in part explain the relative neglect of this topic in the orthopaedic literature.

For assessment of outcome we used charts, questionnaires, and examinations according to a modified Neer's method.<sup>48</sup> Neer's method of assessment was modified, because some patients were unable to attend the clinic for a follow-up examination. This series parallels a previous report<sup>8</sup> in the degree of difficulty in obtaining follow-up in these patients. This finding may be accounted for by an elderly population,

\*References 1, 6, 8, 11, 13, 14, 21, 22, 25, 27, 37-39, 45, 47, 49, 51, 56, 57, 62-67.

†References 8, 13, 14, 22, 38, 39, 45, 47, 51, 56, 62-67.

time interval between injury and review, and a large transient population.<sup>8</sup>

Previous studies have commented on the general condition of patients with a surgical neck fracture.<sup>10, 24, 53</sup> In this patient group significant medical problems may suggest that surgical treatment is not a reasonable choice.<sup>10, 53</sup> In this study 38.1% of patients with a surgical neck fracture had significant medical problems.

Several authors have recommended conservative treatment for surgical neck fractures.<sup>11, 14, 20, 65</sup> However, no clear description existed of what conservative treatment measures entail and what criteria are used to select them. We selected the method of treatment according to the situation. A sling and exercises is preferred for uncomplicated, stable fractures with an acceptable position. The weight of the arm is approximately 10 or 15 lb.<sup>40</sup> The weight of the arm alone is sufficient to reduce or correct the fracture completely in some cases, and it never accentuated malalignment of the fracture.<sup>13, 14</sup> The sling should permit the arm to hang loosely at the side of body,<sup>13, 50</sup> because a sling that is too tight may aggravate the deformity.<sup>3, 4, 13</sup> A hanging arm cast invites an increased risk of nonunion because of distraction.<sup>13, 14, 53</sup> Recent reports have highlighted the long-term deficiencies of humeral mobility after treatment with a hanging arm cast.<sup>7</sup> Thus we feel strongly that a hanging arm cast is not only unnecessary but is also risky.

The role of exercise in proximal humerus fractures has been a point of continued contention. Although some authors have contended that early exercise contributes to delayed union and nonunion,<sup>50, 53</sup> Alldredge and Knight<sup>1</sup> and Brostrom<sup>6</sup> have reported that early motion even in unstable fractures produced no further displacement of fragments. Many other reports have pointed out the importance of early mobilization.\* Clifford<sup>8</sup> commented that the detrimental effects of prolonged rest, which include muscle atrophy, fibrosis of muscle, and contracture of the joint capsule and ligament, cannot always be eliminated by longer physiotherapy. Furthermore, these changes have been noted to occur extremely rapidly,<sup>1</sup> especially in the deltoid muscle.<sup>21</sup> We recommended early

motion with finger and wrist exercises beginning at the time of initial treatment. Gentle pendulum exercises were begun 1 to 2 days after the fracture, when the patient was comfortable. Isometric exercises were begun between day 1 and day 7 at the discretion of the treating surgeon. In cases with significant angulation of the fracture, isometric exercises were delayed until at least day 7, when the coagulation had been corrected. Increasing activities were permitted for each patient within the limits of pain tolerance for each individual treated.

We believe that early exercise is an integral part of the treatment of these fractures. Part of this program is isometric exercise, which has been largely ignored except for a report by Young and Wallace.<sup>65</sup> We prefer to instruct the patients personally and agree with Bertoft et al.<sup>2</sup> and Lundberg et al.<sup>41</sup> that this is an effective method. All exercises should be done under the direction of the treating surgeon.<sup>10</sup>

Skeletal traction was used in treating 13 patients in this series. The indications for treating these patients in traction included unstable fractures after reduction, failure of closed reduction, and open fractures. Overhead traction was applied through the olecranon process, and frequent follow-up radiographs are essential. When the patient complained of less pain, and early callus appeared on radiographs, the arm was gradually moved to the side of the patient over a course of several days. When motion no longer occurred at the fracture site, and good callus formation was seen with radiography, the traction was discontinued, and a sling was applied. The main disadvantage of skeletal traction is confinement in bed during traction; however, the brief confinement for 3 to 4 weeks is usually tolerable for most patients. The other disadvantages of skeletal traction include stiffness of the elbow and shoulder<sup>53</sup> and the difficulty of application,<sup>3, 4</sup> but in many situations this form of treatment is preferable to operative intervention.

Some authors have recommended manipulation as the treatment of choice for surgical neck fractures,<sup>19, 31</sup> and Svend-Hansen<sup>63</sup> reported the improved results manipulative treatment afforded. Other reports have emphasized the risks of manipulation<sup>13, 44</sup> and the possibility for redisplacement.<sup>65</sup> Of the 38 patients treated with closed reduction in this series, a satisfactory position was obtained in 33 cases, and in

\*References 8, 12-14, 16, 17, 28, 34, 46, 47, 65.

24 of the cases the reduction was stable. Of the 24 cases with a stable reduction, a sling and exercises was used in 20 cases. In the nine cases of unstable reduction, skeletal traction was used. The success of manipulative treatment may be improved by the addition of percutaneous pinning,<sup>3, 4, 26</sup> although too few cases are in this series to draw any conclusions.

Although many operative methods have been described in the treatment of surgical neck fractures,\* the indications for operative treatment have remained unclear. We believe the indications for operative treatment include failure of conservative measures, intolerance of patients to conservative treatment, selective cases of multiple trauma, open fractures, and vascular injury. Patients must be fully aware of the risks operative treatment entails and the expected result.<sup>14</sup>

Some authors have recommended anatomic reduction as a necessary component in the treatment of surgical neck fractures.<sup>47, 61</sup> However, the multiaxial motion of the glenohumeral joint and scapulothoracic motion preclude the necessity for anatomic reduction.<sup>50, 65</sup> Several authors<sup>13, 29, 46, 65</sup> have demonstrated that no correlation exists between the anatomic result and functional result, patient's satisfaction, or the amount of pain. An acceptable function for activities of daily living in this group includes being able to place the hand on the back of the head and to the ipsilateral sacroiliac joint.<sup>29</sup> In elderly, ill patients, accepting some functional loss rather than enjoining the risks of surgical treatment is a realistic choice.<sup>10, 14, 53, 59</sup>

Only 24 cases of greater tuberosity fracture appear in this series. Horak and Nisson<sup>24</sup> have commented that the epidemiology of greater tuberosity fractures deviated from the pattern of other proximal humerus fractures. DePalma and Cautilli<sup>13</sup> commented that this injury was more prevalent in female patients. Furthermore Flatow et al.<sup>18</sup> reported an average age for this fracture of 53 years but with a slight male predominance. Our findings diverge from these previous reports. The average age of the patients treated for greater tuberosity fractures was 37 years, and 19 of the 24 patients were men.

In 13 cases, after reduction of the anterior

dislocation, anatomic reduction of the greater tuberosity fracture was obtained. McLaughlin<sup>43</sup> has suggested that this fracture is usually well reduced by the remaining periosteal sleeve. The periosteal sleeve may contribute to reduction of this fracture; however, late redisplacement of the fracture is a well-recognized phenomenon.<sup>3, 4, 42</sup> Therefore frequent radiographic examination of these fractures is necessary. We used a three-view trauma series radiographic examination for determining the displacement, including a true anterior-posterior, a lateral, and an axillary lateral radiograph of the shoulder. In selected cases internal and external rotation views were obtained, and, rarely, computed tomography was used.

Ten cases required open reduction and internal fixation of the greater tuberosity fracture. Eight of these cases were stabilized with screws, although a number of other fixation methods have been described.<sup>18, 51, 52, 54</sup> In one case of screw fixation, screw loosening occurred. Although suture fixation will avoid this potential problem,<sup>18</sup> we prefer screw fixation for secure internal fixation.

Anatomic neck and lesser tuberosity fractures are extremely rare injuries,\* and together they total only four cases in this series. Conservative measures have been advocated by most authors<sup>3, 4, 60</sup> in the treatment of lesser tuberosity fractures, although Earwaker<sup>15</sup> suggests operative treatment. In this series both lesser tuberosity fractures were successfully managed with conservative measures. Anatomic neck fractures, however, typically require operative intervention.<sup>13</sup> The complications of anatomic neck fractures are well recognized, most notably avascular necrosis.<sup>3, 4</sup> Unfortunately no evaluation was possible in either patient with this injury.

## CONCLUSION

The treatment of two-part fractures of the proximal humerus must be individualized. The method of treatment selected should be based not only on the fracture configuration but also on the patient's general status. For surgical neck fractures a simple sling with early controlled exercises, under the surgeon's control, resulted in an acceptable functional outcome in

\*References 5, 26, 32, 35, 47, 51, 57, 58, 64, 66, 67.

\*References 3, 4, 13, 15, 25, 48, 60.

this series. Similarly, early fixation for displaced greater tuberosity fractures resulted in a good functional outcome. Anatomic neck and lesser tuberosity fractures are extremely rare; lesser tuberosity fractures appear to do well with conservative treatment, whereas anatomic neck fractures may require operative intervention.

## REFERENCES

1. Alldredge RH, Knight MP. Fractures of the upper end of the humerus treated by early relaxed motion and massage. *New Orleans Med Surg J* 1940;92:519-24.
2. Bertoft ES, Lundh I, Ringqvist I. Physiotherapy after fracture of the proximal end of the humerus, comparison between two methods. *Scand J Rehabil Med* 1984; 16:11-6.
3. Bigliani LU. Fractures of the proximal humerus. In: Rockwood CA, Green DP, Bucholz RW, editors. 3rd ed. Fractures in adults. Philadelphia: JB Lippincott, 1991:871-927.
4. Bigliani LU. Fractures of the proximal humerus. In: Rockwood CA, Matsen FA, editors. The shoulder. Philadelphia: WB Saunders, 1990:278-334.
5. Bosworth DM. Blade plate fixation. *JAMA* 1949;141: 1111-3.
6. Brostrom F. Early mobilization of fractures of the upper end of the humerus. *Arch Surg* 1943;46:614-5.
7. Ciernik IF, Meirer L, Hollinger A. Humeral mobility after treatment with hanging cast. *J Trauma* 1991;31:230-3.
8. Clifford PC. Fractures of the neck of the humerus: a review of the late results. *Injury* 1980;12:91-5.
9. Codman EA. Rupture of the supraspinatus tendon and other lesions in or about the subacromial bursas. In: Codman EA, editor. The shoulder. Brooklyn, New York: G Miller & Co Medical Publishers, 1934:262-331.
10. Cofield RH. Comminuted fractures of the proximal humerus. *Clin Orthop* 1988;230:49-57.
11. Dehne E. Fractures at the upper end of the humerus. *Surg Clin North Am* 1945;25:28-47.
12. DePalma AF. Fractures of the proximal humerus. In: Surgery of the shoulder. 3rd ed. Philadelphia: JB Lippincott, 1983:372-402.
13. DePalma AF, Cautilli RA. Fractures of the upper end of the humerus. *Clin Orthop* 1961;2:73-92.
14. Drapanas T, McDonald J, Hale HW Jr. A rational approach to classification and treatment of fractures of the surgical neck of the humerus. *Am J Surg* 1960;99:617-24.
15. Earwaker J. Isolated avulsion fracture of the lesser tuberosity of the humerus. *Skeletal Radiol* 1990;19:121-5.
16. Editorial. Proximal humeral fractures. *Injury* 1981;12:89-90.
17. Ekström T, Lagergren C, von Schreeb T. Procaine injections and early mobilisation for fractures of the neck of the humerus. *Acta Chir Scand* 1965;130:18-24.
18. Flatow EL, Cuomo F, Maday MG, Miller SG, McIlveen S, Bigliani LU. Open reduction and internal fixation of two-part displaced fractures of the greater tuberosity of the proximal part of the humerus. *J Bone Joint Surg [Am]* 1991;73A:1213-8.
19. Frankau C, Lond MS. A manipulative method for the reduction of fractures of the surgical neck of the humerus. *Lancet* 1933;2:755.
20. Garceau GJ, Cogland S. Early physical therapy in the treatment of fractures of the surgical neck of the humerus. *Indiana Med* 1941;34:293-5.
21. Gurd FB. A simple effective method for the treatment of fractures of the upper two-thirds of the humerus. *Am J Surg* 1940;47:443-53.
22. Hägg O, Ludberg B. Aspects of prognostic factors in comminuted and dislocated proximal humeral fractures. In: Bateman JE, Welsh RP, editors. Surgery of the shoulder. Philadelphia: BC Decker, 1984:51-9.
23. Hall MC, Rosser M. The structure of the upper end of the humerus, with reference to osteoporotic changes in senescence leading to fractures. *Can Med Assoc J* 1963;88:290-4.
24. Horak J, Nisson BE. Epidemiology of fracture of the upper end of the humerus. *Clin Orthop* 1975;112:251-3.
25. Howard NJ, Eloesser L. Treatment of fractures of the upper end of the humerus: an experimental and clinical study. *J Bone Joint Surg* 1934;16:1-29.
26. Jakob RP, Kristiansen T, Mayo K, Ganz R, Müller ME. Classification and aspects of treatment of fractures of the proximal humerus. In: Bateman JE, Welsh RP, editors. Surgery of the shoulder. Philadelphia: BC Decker, 1984:330-43.
27. Keene JS, Huizenga RE, Engber WD, Rogers SC. Proximal humeral fractures, a correlation of residual deformity with long term function. *Orthopedics* 1983;6: 173-8.
28. Kiær T. Fractures of the proximal humerus: the relation of Neer classification to the course of healing. *Acta Orthop Scand* 1985;56:544-5.
29. Knight RA, Mayne JA. Comminuted fractures and fracture-dislocations involving the articular surface of the humeral head. *J Bone Joint Surg [Am]* 1957;39A:1343-55.
30. Kocher T. Die Fracturen am oberen Humerusende. In: Kocher T, editor. Beiträge zur Kenntnis einiger praktisch wichtiger Fracturformen. Basel, Switzerland: Carl Sallman Verlag, 1896:591-675.
31. Kristiansen B. Displaced fractures of the proximal humerus. *Acta Orthop Scand* 1985;56:544.
32. Kristiansen B. External fixation of proximal humerus fracture, clinical and cadaver study of pinning technique. *Acta Orthop Scand* 1987;58:645-8.
33. Kristiansen B, Andersen ULS, Olsen CA, Varmarken J-E. The Neer classification of fractures of the proximal humerus. *Skeletal Radiol* 1988;17:420-2.
34. Kristiansen B, Angermann P, Larsen TK. Functional results following fractures of the proximal humerus, a controlled clinical study comparing two periods of immobilization. *Arch Orthop Trauma Surg* 1989;108:339-41.
35. Kristiansen B, Christensen SW. Plate fixation of proximal humeral fractures. *Acta Orthop Scand* 1986;57:320-3.
36. Kristiansen B, Christensen SW. Proximal humeral fractures, late results in relation to classification and treatment. *Acta Orthop Scand* 1987;58:124-7.
37. Lee CK, Hansen HR. Post-traumatic avascular necrosis of the humeral head in displaced proximal humeral fractures. *J Trauma* 1981;21:788-91.
38. Leyshon RL. Closed treatment of fractures of the proximal humerus. *Acta Orthop Scand* 1984;55:48-51.

39. Lind T, Krøner K, Jensen J. The epidemiology of fractures of the proximal humerus. *Arch Orthop Trauma Surg* 1989;108:285-7.
40. Lovett RW. The diagnosis and treatment of some common injuries of the shoulder joint. *Surg Gynecol Obstet* 1922;34:437-44.
41. Lundberg BJ, Svenungson-Hartwig E, Wikmark R. Independent exercises versus physiotherapy in nondisplaced proximal humeral fractures. *Scand J Rehabil Med* 1979;11:133-6.
42. Macpherson IS, Crossan JF, Allister CA. Unstable fractures of the greater tuberosity of the humerus. *J Bone Joint Surg [Br]* 1983;65B:225.
43. McLaughlin HL. Dislocation of the shoulder with tuberosity fracture. *Surg Clin North Am* 1963;43:1615-20.
44. Miller SR. Practical points in the diagnosis and treatment of fractures of the upper fourth of the humerus. *Indust Med* 1940;9:458-60.
45. Mills H, Horne G. Fractures of the proximal humerus in adults. *J Trauma* 1985;25:801-5.
46. Mills KLG. Severe injuries of the upper end of the humerus. *Injury* 1975;6:13-21.
47. Moda SK, Chadha NS, Sangwan SS, Khurana DK, Dahiya AS, Siwash RC. Open reduction and fixation of proximal humeral fractures and fracture-dislocations. *J Bone Joint Surg [Br]* 1990;72B:1050-2.
48. Neer CS. Displaced proximal humeral fractures, Pt I. *J Bone Joint Surg [Am]* 1970;52A:1077-89.
49. Neer CS. Displaced proximal humeral fractures, Pt II. *J Bone Joint Surg [Am]* 1970;52A:1090-103.
50. Neviaser JS. Complicated fractures and dislocations about the shoulder joint. *J Bone Joint Surg [Am]* 1962;44A:984-98.
51. Paavolainen P, Björkenheim J-M, Slätis P, Pauku P. Operative treatment of severe proximal humeral fractures. *Acta Orthop Scand* 1983;54:374-9.
52. Phemister DB. Fractures of the greater tuberosity of the humerus. *Ann Surg* 1912;56:440-9.
53. Post M. Fractures of the upper humerus. *Orthop Clin North Am* 1980;11:239-52.
54. Roberts SM. Fractures of the upper end of the humerus. *JAMA* 1932;98:367-73.
55. Rose SH, Melton J, Morrey BF, Ilstrup DM, Riggs BL. Epidemiologic features of humeral fractures. *Clin Orthop* 1982;168:24-30.
56. Savoie FH, Geissler WB, Vander Griend RA. Open reduction and internal fixation of three-part fractures of the proximal humerus. *Orthopedics* 1989;12:65-70.
47. Sehr JR, Szabo RM. Semitubular blade plate for fixation in the proximal humerus. *J Orthop Trauma* 1989;2:327-32.
58. Seide H. Humeral locking nail. *Orthopedics* 1989;12:219-26.
59. Sever JW. Fracture of the head of the humerus, treatment and results. *N Engl J Med* 1937;216:1100-7.
60. Shibuya S, Ogawa K. Isolated avulsion fracture of the lesser tuberosity of the humerus: a case report. *Clin Orthop* 1986;211:215-8.
61. Solonen KA, Vastamäki M. Osteotomy of the neck of the humerus for traumatic varus deformity. *Acta Orthop Scand* 1985;56:79-80.
62. Sturzenegger M, Fornaro E, Jakob RP. Results of surgical treatment of multifragmented fractures of the humeral head. *Arch Orthop Trauma Surg* 1982;100:249-59.
63. Svend-Hansen H. Displaced proximal humeral fractures, a review of 49 patients. *Acta Orthop Scand* 1974;45:359-64.
64. Yamano Y. Comminuted fractures of the proximal humerus treated with hook plate. *Arch Orthop Trauma Surg* 1986;105:359-63.
65. Young TB, Wallace WA. Conservative treatment of fractures and fracture-dislocations of the upper end of the humerus. *J Bone Joint Surg [Br]* 1985;67B:373-7.
66. Zifco B, Poigenfürst J, Pezzei C, Stockley I. Flexible intramedullary pins in the treatment of unstable proximal humeral fractures. *Injury* 1991;22:60-2.
67. Zifco B, Zifco B, Poigenfürst J. Die Behandlung unstabiler Frakturen am proximalen Humerusende durch elastische Vorgebogene Markdrähte. *Unfallchirurgie* 1987;13:72-81.

### 1-800-55-MOSBY

This number links you to the full text of literally every article ever published in Mosby journals. *MOSBY Document Express*,™ a rapid response information retrieval service, provides quick turnaround, 24-hour availability, and speedy delivery methods. For inquiries and pricing information, call our toll-free, 24-hour order line: 1-800-55-MOSBY; outside the U.S.: 415-259-5046; fax: 415-259-4019; E-mail: mosbyexp@class.org.

*MOSBY Document Express*™ is offered in cooperation with Dynamic Information Corp.